

Genitourinary Tract Injuries

Introduction

Genitourinary (GU) injuries constitute approximately 5% of the total injuries encountered in combat. Their treatment adheres to established surgical principles of hemostasis, debridement, and drainage. Proper radiographic evaluation prior to surgery may replace extensive retroperitoneal exploration at the time of laparotomy in the diagnosis of serious GU injuries.

GU wounds, aside from injuries of the external genitalia, are typically associated with serious visceral injury.

Renal Injuries

- Most renal injuries, except for those of the renal pedicle, are not acutely life threatening. Undiagnosed or improperly treated injuries, however, may cause significant morbidity.
- While the vast majority of blunt renal injuries will heal uneventfully with observation and conservative therapy, a significant number of renal injuries in combat will come from penetrating wounds and require exploration.

The evaluation of a suspected renal injury is based on the type of injury, physical examination, and urinalysis.

- Hematuria is usually present in patients with renal trauma, and gross hematuria in the adult patient is concerning for a significant injury. **The absence of hematuria, however, does not exclude renal trauma.** Renal injury must be suspected in patients who have sustained significant concurrent injuries such as multiple rib fractures, vertebral body or transverse process fractures, crushing injuries of the chest or thorax, or penetrating injury to the flank, chest, or upper abdomen.

- Adult patients who present with gross hematuria, microscopic hematuria with shock at any time following the injury, and significant concurrent injury require further evaluation of their kidneys. Computed tomography (CT) provides excellent staging of renal injuries and aids in the decision whether or not to explore the injured kidney.
- In the combat setting, many patients require rapid exploration before definitive radiographic staging can be completed. An intraoperative single-shot intravenous pyelogram (IVP) is useful in their evaluation.
 - Procedure for one-shot IVP:
 - ◆ 2 cc/kg of high-dose contrast is injected in either the ED or OR setting.
 - ◆ A single standard KUB radiograph is obtained 10 minutes following the contrast injection.
 - While high-osmolality contrast (Renografin, Hypaque, or Conray) is adequate, low-osmolality contrast (Omnipaque, Isovue, Optiray) is less likely to generate a reaction and is less toxic to the kidney.
- Major renal injuries usually appear as obscured renal shadows on IVP.
 - Detailed anatomic information regarding the degree of renal injury or presence of urinary extravasation should not be expected on the trauma IVP. Delayed films, however, may improve detection of urinary extravasation.
 - The study should confirm the presence and function of the **contralateral** kidney and may demonstrate congenital anomalies such as renal ectopia or fusion. Understanding the function of the contralateral kidney is imperative to sound intraoperative decision making during exploration and possible salvage of the injured kidney.
- Renal trauma is categorized by the extent of damage to the kidney.
 - Minor injuries.
 - ◆ Consist of renal contusions or shallow cortical lacerations.
 - ◆ Most common after blunt trauma and usually resolve safely without renal exploration.
 - ◆ Hydration, antibiotics, and bed rest are the cornerstones of successful nonoperative management.

- o Major injuries.
 - ◆ Consist of deep cortical lacerations (with or without urinary extravasation), shattered kidneys, renal vascular pedicle injuries, or total avulsion of the renal pelvis.
 - ◆ There is an 80% incidence of associated visceral injuries with major renal trauma. Most cases will require a laparotomy for evaluation and repair of concurrent intraperitoneal injuries.
 - ◆ Operative intervention includes debridement of nonviable renal tissue (partial nephrectomy), closure of the collecting system, and drainage of the retroperitoneal area.
 - ◆ Kidney preservation should be considered if at all possible, although total nephrectomy may be required for the severely damaged kidney or the unstable patient.

Vascular control of the renal pedicle can be obtained prior to opening the perirenal fascia when control of hemorrhage from the kidney requires exploration of the retroperitoneum.

- **Operative Technique.**
 - o Obtain vascular control from a periaortic approach to the renal vascular pedicle.
 - ◆ The small intestine is retracted laterally and superiorly, and the posterior peritoneum is incised over the aorta.
 - ◆ The left renal vein, crossing anterior to the aorta, must be mobilized to gain control of either renal artery.
 - ◆ Atraumatic vascular clamps are used to occlude the appropriate artery.
 - o While vascular control in this fashion may provide the safest approach against renal hemorrhage and reduce the likelihood of nephrectomy, it is not a commonly performed maneuver by either urologists or general surgeons. Direct reflection of the colon to expose the kidney is feasible (Fig. 18-1). A kidney pedicle clamp should be readily available for this approach.

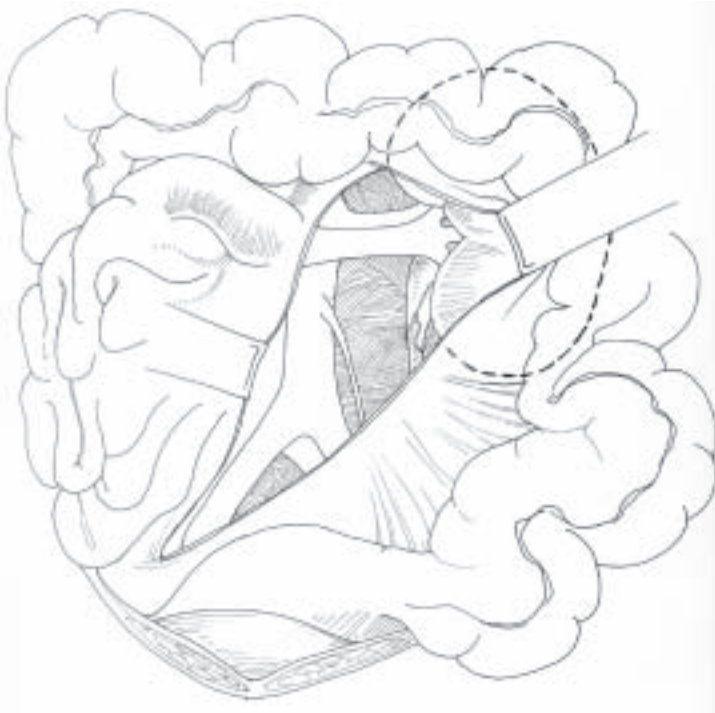


Fig. 18-1. Exposure of left renal hilum.

- o Damaged renal parenchyma can be locally debrided (Fig. 18-2), excised in a partial nephrectomy (Fig. 18-3), or removed in a total nephrectomy depending on the degree of injury and the condition of the patient.

Nephrectomy may be the best solution for major renal injuries when associated life-threatening injuries are present.

- o Watertight closure of the collecting system with absorbable suture prevents the development of a urine leak.
 - ◆ Urinary diversion is typically unnecessary if formal renal reconstruction is accomplished.

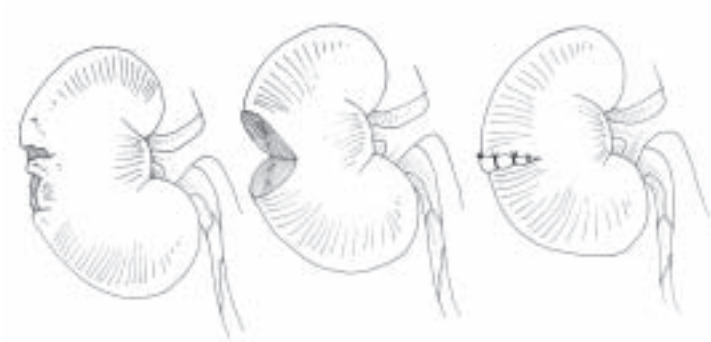


Fig. 18-2. Steps in renal debridement.

- ◇ For the sake of expedience or in the presence of associated injuries of the duodenum, pancreas, or large bowel, diversion may be required.
- ◇ Tube nephrostomy, ureteral stent, or ureterostomy may be utilized.
- o The reconstructed kidney should be covered by perirenal fat, omentum, or fibrin sealant.
- o A closed suction drain should be left in place.

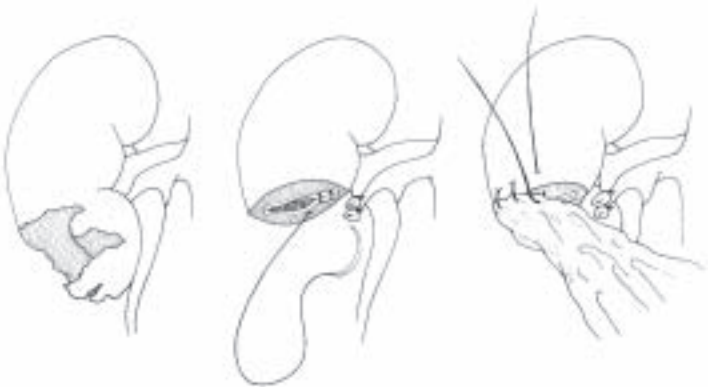

Fig. 18-3. Steps in partial nephrectomy.

Ureteral Injuries

Ureteral injuries are rare but are frequently overlooked when not appropriately considered. They are more likely in cases of retroperitoneal hematoma and injuries of the fixed portions of the colon, duodenum, and spleen.

- Isolated ureteral injuries are rare and usually occur in conjunction with other significant injuries. They can represent a difficult diagnostic challenge in both the preoperative and intraoperative settings.
 - Ureteral injuries are not reliably diagnosed by the preoperative IVP.
 - Hematuria is frequently absent.
 - Blast injury to the urethra may produce significant delayed complications even when the IVP is normal and the ureter appears visibly intact. Placement of an indwelling stent is reasonable when a high-velocity or blast injury occurs in proximity to the ureter.
 - If a ureteral injury is initially missed and presents in a delayed fashion, urinary diversion with a nephrostomy tube and delayed repair at 3–6 months is a safe approach.

- Operative Technique.
 - Intraoperative localization of the ureteral injury is facilitated by IV injection of indigo carmine or direct injection into the collecting system under pressure.
 - Basic principles of repair.
 - ◆ Minimal debridement.
 - ◆ Primary tension free, 1 cm spatulated anastomosis using an interrupted single-layer absorbable suture (4-0 or 5-0) closure technique.
 - ◆ Internal (double J ureteral stent) and external drainage.
 - ◆ Lengthening maneuvers.
 - ◇ Ureteral mobilization.
 - ◇ Kidney mobilization.
 - ◇ Psoas hitch (Fig. 18-4).
 - ◇ Boare flap.

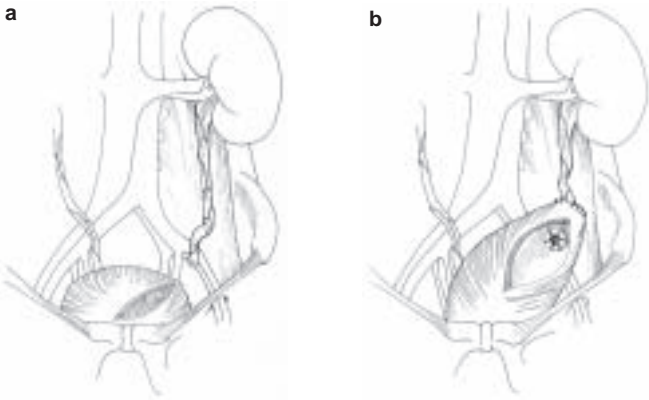


Fig. 18-4. The psoas hitch.

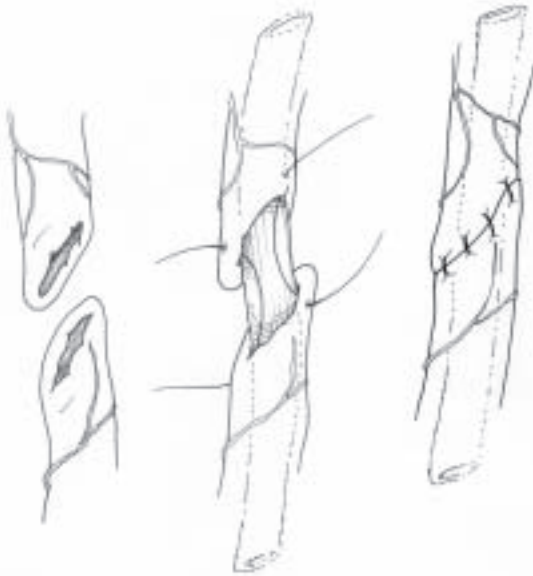

Fig. 18-5. Ureteroureterostomy.

- ◆ Isolate repairs with omentum or posterior peritoneum.
- o The type of repair is based on the following:
 - ◆ Anatomical segment of the traumatized ureter (upper, middle, and lower third).
 - ◆ Extent of segmental loss.
 - ◆ Other associated injuries.
 - ◆ Clinical stability of the patient.
- o Upper or Middle ureteral injuries:
 - ◆ Short segment loss/transection: Perform a primary ureteroureterostomy (Fig. 18-5).
 - ◆ Long segment loss: May require a temporizing tube/cutaneous ureterostomy with stent placement or ureteral ligation with tube nephrostomy.
- o Lower ureteral injuries.
 - ◆ When the injury occurs near the bladder, an ureteroneocystostomy should be performed (Fig. 18-6). This is typically completed by fixing the bladder to the fascial covering of the psoas muscle using permanent suture such as 2.0 or 3.0 Prolene. A transverse cystotomy assists in elongating the bladder to that location and facilitates the development of a submucosal tunnel for the reimplanted ureter.
 - ◆ When a distal ureteral injury is associated with a rectal injury, ureteral reimplantation is not recommended; temporary diversion should be performed.

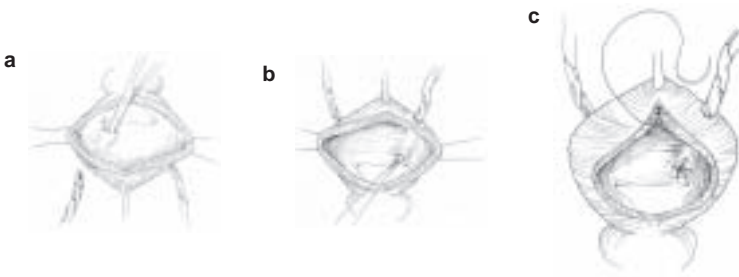


Fig. 18-6. Ureteroneocystostomy.

Ureteral injuries in the combat setting may be best managed with temporary tube drainage with a small feeding tube or ureteral stent followed by delayed reconstruction.

Bladder Injuries

Bladder wounds should be considered in patients with lower abdominal gunshot wounds, pelvic fractures with gross hematuria, or those patients unable to void following abdominal or pelvic trauma.

- Bladder disruptions can occur on the intraperitoneal or extraperitoneal surface of the bladder. The location may change the symptoms, complications, and management of this injury.
- After ensuring urethral integrity in appropriate cases (see Urethral Injuries, below), evaluation of the bladder is performed radiographically with a cystogram.
 - Cystography is performed using a 3-film technique: (1) scout or plain film KUB concentrating on the pelvis, (2) full-bladder radiograph after retrograde filling of the bladder with contrast, and (3) a postdrainage radiograph.
 - **Technique:** Fill the bladder by gravity with a urethral catheter using radiopaque contrast medium elevated 20–30 cm above the level of the abdomen. At least 300 cc (5–7 cc/kg in children) are required for an adequate study. Take a full-bladder radiograph.
 - Drain the bladder using the catheter and take a postdrainage radiograph. Small extraperitoneal areas of extravasation may be apparent only on the postevacuation film.
- Operative Technique.
 - Intraoperative Injuries.
 - ◆ Cystography reveals contrast medium interspersed between loops of bowel.
 - ◆ Management consists of immediate exploration, multilayer repair of the injury with absorbable suture, suprapubic tube cystostomy, and drainage of the

- perivesical extraperitoneal space.
- o Extraperitoneal injuries.
 - ◆ Bladder laceration is most often the result of laceration by bony fragments from a pelvic fracture.
 - ◆ Cystography reveals a dense, flame-like extravasation of contrast medium in the pelvis on the postevacuation film.
 - ◆ The bladder usually heals with 10–14 days of Foley catheter drainage without the need for primary repair. If the urine is clear, catheter drainage alone is preferred for treatment of most extraperitoneal ruptures.
 - ◆ In cases of abdominal exploration for other injuries, primary repair and drainage are necessary if the extraperitoneal space is entered. Repair can be completed from inside the bladder through a cystotomy to avoid disturbing any pelvic hematoma. Patients with concurrent rectal injuries should be managed more aggressively and may benefit from hematoma evacuation and primary bladder repair.

Urethral Injuries

A urethral injury should be suspected in patients with a scrotal hematoma, blood at the meatus, or a floating/high-riding prostate. Catheterization is contraindicated until urethral integrity is confirmed by retrograde urethrography.

- Retrograde urethrography is performed to evaluate the anatomy of the urethra.
 - o Take oblique radiographs of the pelvis to avoid “end-on” imaging that obscures the bulbar urethra.
 - o Insert the end of a sterile catheter tip syringe (60 cc) into the urethral meatus while grasping the glans to prevent leakage. Alternately, insert an unlubricated Foley catheter into the fossa navicularis (approximately 3 cm) and inflate the balloon with 3 cc of water.
 - o Gently instill 15–20 cc of water-soluble contrast. The radiograph is taken during injection.

- o Contrast must be seen flowing into the bladder to clear the proximal urethra of injury. Posterior urethral injuries seen in pelvic fractures may be missed otherwise.
- o If no injury is identified, carefully place a Foley catheter.

If any difficulty in passing the catheter is encountered, the urethra should not be instrumented and a suprapubic tube cystostomy is performed.

- Operative Technique.
 - o The urethra is divided into **anterior** and **posterior** (prostatic) segments by the urogenital diaphragm.
 - ◆ Anterior urethral injuries may result from blunt trauma, such as results from falls when astride an object (straddle) or from penetrating injuries.
 - ◇ Blunt trauma resulting in minor nondisruptive urethral injuries may be managed by gentle insertion of a 16 French Foley catheter for 7–10 days.
 - ◇ Penetrating wounds should be managed by exploration and judicious debridement.
 - Small, clean lacerations may be repaired primarily by reapproximation of the urethral edges using interrupted 4-0 chromic suture.
 - Do not mobilize the entire urethra for a primary anastomosis, because the shortened urethral length in the pendulous urethra may produce ventral chordee and an anastomosis under tension.
 - Instead, marsupialize the injured urethral segment by suturing the skin edges to the cut edges of the urethra. Marsupialization should be performed until healthy urethra is encountered both proximally and distally. Closure of the marsupialized urethra is subsequently performed at 6 months to reestablish urethral continuity.
 - ◆ Posterior urethral disruption commonly occurs following pelvic fracture injuries.
 - ◇ Rectal examination reveals the prostate to have been avulsed at the apex.

- ◇ Improved continence and potency rates are attained when suprapubic tube cystostomy is used as the initial management.
- ◇ Suprapubic urinary diversion is maintained for 10–14 days and urethral integrity is confirmed radiographically prior to removal of the suprapubic tube.
- ◇ With expectant observation, virtually all these injuries will heal with an obliterative prostatomembranous urethral stricture, which can be repaired secondarily in 3–6 months after reabsorption of the pelvic hematoma.
- ◇ Initial exploration of the pelvic hematoma is strictly reserved for patients with concomitant bladder neck or rectal injury.

External Genitalia Injuries

The management of wounds to the penis, scrotum, testes, or spermatic cord should be as conservative as possible and consists of hemorrhage control, debridement, and early repair to prevent deformity.

- Injuries to the penis that disrupt Buck's fascia should be sutured to prevent further bleeding and avoid future penile curvature with erection. When extensive penile skin is lost, the penis may be placed in a scrotal tunnel until a plastic repair can be performed.
- The scrotum is highly vascularized, and extensive debridement is usually not necessary for scrotal wounds.
 - Most penetrating scrotal injuries should be explored to evaluate the testicle for injury and reduce the risk of hematoma formation.
 - Most partial scrotal avulsions are best treated by primary closure with absorbable 3-0 sutures in two layers.
 - Primary closure is selected for patients without associated life-threatening injuries who sustained injury less than 8 hours prior. A Penrose drain or small closed drain can be placed to reduce hematoma formation. The testes can be

placed in protective pockets in the medial thigh for complete scrotal avulsion.

- It is essential, when dealing with testicular wounds, to conserve as much tissue as possible.
 - Herniated parenchymal tissues should be debrided, and the tunica albuginea closed by mattress sutures.
 - The testicle is placed in the scrotum or in a protective pocket in the medial thigh.
 - A testicle should never be resected unless it is hopelessly damaged and its blood supply destroyed.

